

---

# The Effect of Monosodium Glutamate (Msg) Administration to Pyramidal Cells Necrosis on Cerebral Cortex of Wistar Male Rats (*Rattus Norvegicus*)

The Effect of  
Monosodium

187

---

Nur Fardian

*Medical School, Universitas Malikussaleh, Lhokseumawe, Indonesia*

Meutia Maulina

*Medical School, Universitas Malikussaleh, Lhokseumawe, Indonesia*

M. Fadhlan La Tabari

*Medical School, Universitas Malikussaleh, Lhokseumawe, Indonesia*

Mardiati

*Medical School, Universitas Malikussaleh, Lhokseumawe, Indonesia*

## Abstract

**Purpose** – The objective of the present study was to determine the effect of monosodium glutamate (MSG) administration to pyramidal cells necrosis on the cerebral cortex of Wistar male rats (*Rattus norvegicus*).

**Design/Methodology/Approach** – This research was a laboratory quasi-experiment study with post-test control group design on 24 male Wistar rats (*Rattus norvegicus*) aged 8-10 weeks, weighted  $200 \pm 10$  gr, divided into 4 groups (GI or control group, GII treated with MSG dose 6 mg/grbb/day, GIII 12 mg/grbb/day, and GIV 24 mg/grbb/day) for 21 days consecutively. Pyramidal cells observed in 10 field of view. The Kruskal-Wallis test and Mann Whitney tests were used to analyze the data.

**Findings** – There were significant differences between pyramidal cells necrosis numbers between control and the treatment groups. MSG doses 6, 12, and 24 mg/grbb/day developed the pyramidal cells necrosis in the cerebral cortex ( $p < 0,005$ ).

**Keywords** cerebral cortex, excitotoxic, monosodium glutamate, necrosis, oxidative, pyramidal cells

*All papers within this proceedings volume have been peer reviewed by the scientific committee of the Malikussaleh International Conference on Multidisciplinary Studies (MICoMS 2017).*



---

© Nur Fardian, Meutia Maulina, M. Fadhlan La Tabari, Mardiati. Published in the Emerald Reach Proceedings Series. Published by Emerald Publishing Limited. This article is published under the Creative Commons Attribution (CC BY 4.0) licence. Anyone may reproduce, distribute, translate and create derivative works of this article (for both commercial and non-commercial purposes), subject to full attribution to the original publication and authors. The full terms of this licence may be seen at <http://creativecommons.org/licenses/by/4.0/legalcode>

Emerald Reach Proceedings Series  
Vol. 1  
pp. 187-192  
Emerald Publishing Limited  
2516-2853  
DOI 10.1108/978-1-78756-793-1-00070

## 1. Introduction

The brain is the most important organ due to its functional role of the central nervous system. It is covered by gray matter, divided into the primary cortex (Snell, 2002). The nervous system uses neurotransmitters to transmit signals (Sherwood, 2010). The glutamate neurotransmitter is one of those mostly used in the brain, with concentration up to 8–12  $\mu$ gr. Excessive stimulation by glutamate will damage or kill nerve cells and may cause excitotoxicity. Monosodium glutamate (MSG) is a flavor enhancer with an umami taste, used broadly in Asia. Average consumption in Asian countries such as China, Thailand and Japan 1.2–1.7 gr daily, with highest consumption 4 gr/day in China (Geha *et al.*, 2000). Daily use of MSG in Indonesia is 0,6 gr/day (Prawirohardjono *et al.*, 2000). Controversies on MSG as food addictive has been discussed. Monosodium glutamate (MSG) caused an increased level of MDA in the liver, kidneys, and brain of rats. Further evidence is needed to find pyramidal cells necrosis on cerebral cortex exposed to MSG in various doses.

## 2. Methods

### 2.1. Design study

The study was conducted in Histology Laboratorium, Faculty of Veterinary of Syiah Kuala University Banda Aceh and Universitas Malikussaleh Lhokseumawe. Twenty male *Rattus norvegicus* aged 8–10 weeks, weighted  $200 \pm 10$  gram were used in this study. Prior to the experiment, all rats were put in acclimatization for one week. BR-2 feeding and normal saline were given during the experiment.

### 2.2. Measurement

Twenty-four male rats divided into 4 groups, each of 6, fed with MSG of 6, 12 and 24 mg/grbw diluted in 1 ml of aquadest via intragastric tube respectively and one remain as control group fed only 200 ml of aquadest for a period of 21 days. On day 22, all rats were terminated, and brain organs were examined to determine pyramidal cells necrosis on the cerebral cortex. Observation used microscope using 400x magnification, under ten fields of view, 5 for external and 5 for the internal pyramidal layer. Necrotic cells were based on the cell nucleus structure, consisted of pyknotic, cariorexix and karyolysis. Necrotic cells of pyramidal were counted in percentage.

### 2.3. Statistical analysis

Variables analyses were conducted using the computerized software. The study used 95% Confident Interval (CI) to detect an association between independent and dependent variables. The data were analyzed by ANOVA ( $\alpha = 0.05$ ), followed by LSD ( $\alpha = 0.05$ ).

## 3. Results

There was a significant difference in external and internal pyramidal layer in histology examination between the control group (GI) and intervention group (GII, GIII, and GIV). In the control group, most of the pyramidal cells were still normal, while in GII, GIII and GIV necrotic cells were found.

Table 1 shows the least necrotic pyramidal cells were in the control group. The higher dose of MSG resulted in a higher percentage of necrotic cells. The highest percentage of necrotic cells were in GIV. Prior to statistical analysis, normality tests are used to determine the normal distribution using the Shapiro-Wilk test and Test of Homogeneity of Variance. Normality tests showed normal distribution of necrotic pyramidal cell percentages ( $p > 0,05$ ), however, variance analysis showed significant differences ( $p < 0,05$ ) thus, Kruskal-

Wallis test then used, instead of One Way ANOVA. Results of Kruskal-Wallis test showed  $p = 0,000$ . This suggested that there was a significant difference between control and intervention groups. ( $p < 0,05$ ). Man-Whitney was then used to identify differences within groups, as shown in Table 2. Based on Table 2, the result showed a significant difference of each group of percentage of necrotic pyramidal cells. Histology examination can be found in Figure 1 and Figure 2.

**Table 1.**

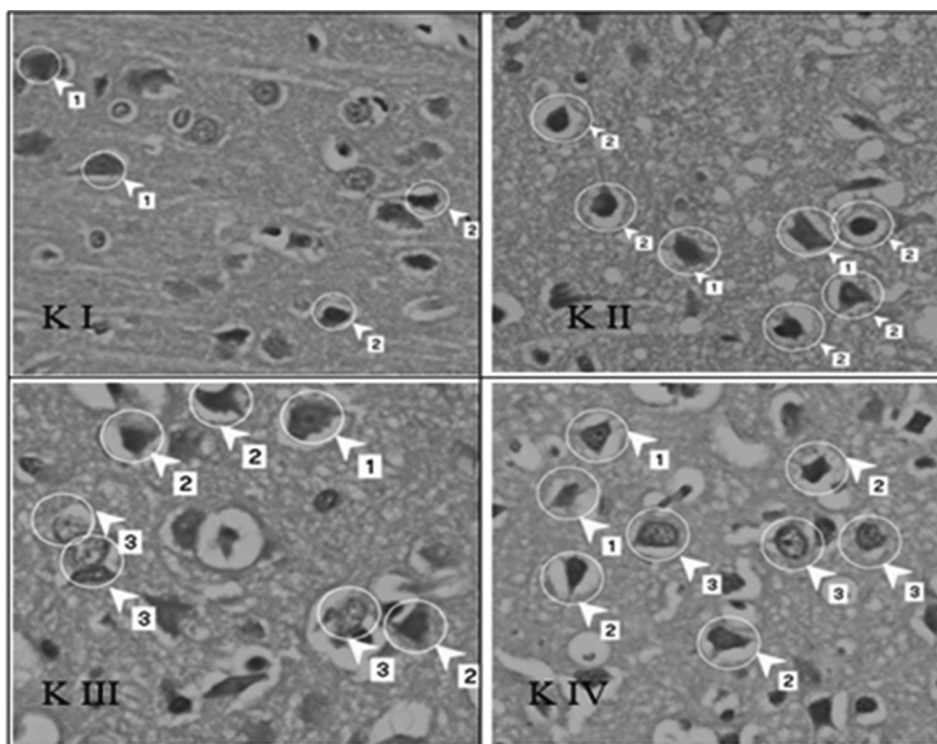
Average score and standard deviation of necrotic pyramidal cells

Groups	<i>n</i>	Total
Control (GI)	6	17.97 ± 4,349
GII (6 mg/bw/day)	6	68.24 ± 1,413
GIII (12 mg/bw/day)	6	85.60 ± 4,277
GIV (24 mg/bw/day)	6	9022 ± 2,256

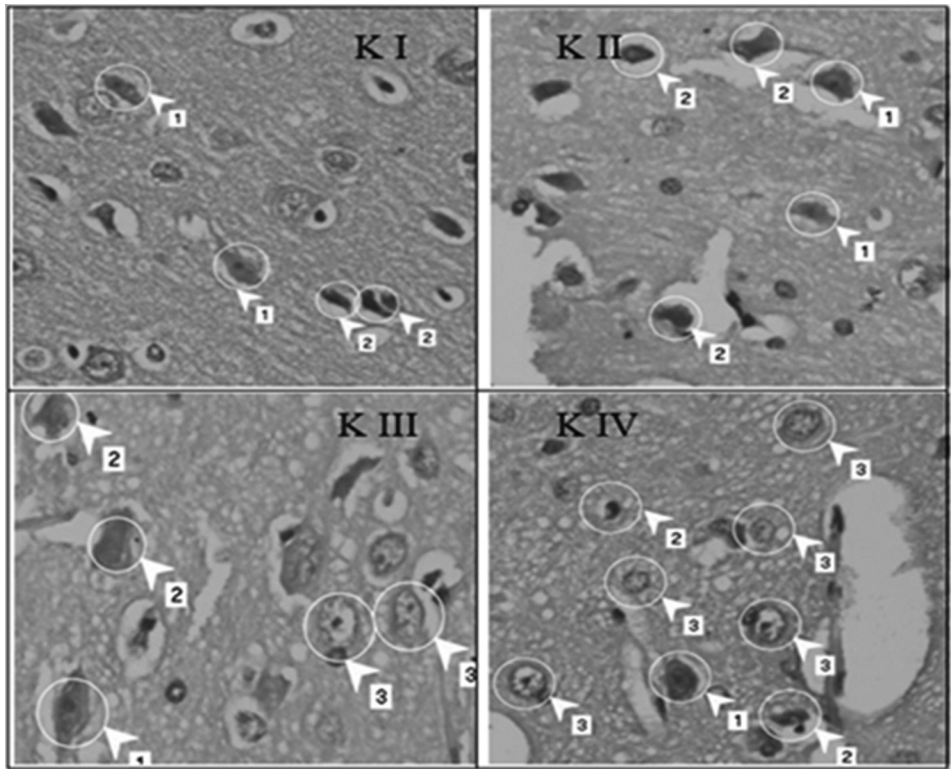
**Table 2.**

Result of Mann-Whitney test of necrotic pyramidal cells

Groups	GI	GII	GIII	GIV
Control (GI)	–	0.004	0.004	0.004
GII (6 mg/bw/day)	–	–	0.010	0.004
GIII (12 mg/bw/day)	–	–	–	0.037
GIV (24 mg/bw/day)	–	–	–	–



**Figure 1.** External pyramidal layer of cortex cerebri. (1) Normal pyramidal cell, (2) Necrotic pyramidal cells, (3) Glya cells. 400x magnification, Hematoxylin and eosin staining



**Figure. 2.**  
An internal  
pyramidal layer of  
cortex cerebri.  
(1) Normal pyramidal  
cell, (2) Necrotic  
pyramidal cells,  
(3) Glya cells. 400x  
magnification,  
Hematoxylin, and  
eosin staining

#### 4. Discussion

Necrotic pyramidal cells were counted by comparing the percentage of necrotic cells between MSG administration groups (MSG 6, 12 and 24 mg/grbw/day) and control group. Based on histology observation, the control group fed only normal saline showed the lowest average percentage ( $17.97 \pm 4,349\%$ ) in comparison to all group of MSG administration. The existence of necrotic cell wins the control group could be caused by stress in rats due to intragastric saline during the experiment. Some studies suggested that stress possibly increase extracellular glutamate concentration and resulted in necrotic pyramidal cells (Prawirohardjono *et al.*, 2000; Bagley *et al.*, 1997; Lupinsky *et al.*, 2010).

The study showed types and duration of administration, as well as the type of stress and rats species used in the experiment, would affect glutamate concentration and consequently resulted in necrosis of pyramidal cells (Mora and G. Segovia, A, 2007). Priyantiningrum *et al.* reported male rats (*Rattus norvegicus*) in routine feeding and received stress restrain for 21 days showed an average of necrotic pyramidal cells  $40.97 \pm 9,06\%$  (Priyantiningrum *et al.*, 2015). Most common found necrotic cell w pyknotic and cell inflammation. Xiong *et al.*, 2009, reported MSG administration caused neuron cell to inflame and necrosis (Xiong *et al.*, 2009). Increased number of the glial cell was also found in all MSG administration group, particularly in GIII and GIV. Increased astrocytes and microglia are related to regulation function in the brain. Astrocytes have a role in homeostasis

and glutamate control in synapse through specific reuptake system (Baehr, M. & Frotscher, 2007; Anurogo and Ikrar, 2014).

MSG administration in GII, GIII, and GIV was proved to increase the percentage of necrotic pyramidal cells in comparison to control group ( $17.97 \pm 4,349\%$ ). Numbers of necrotic of pyramidal cells were relevant to a higher dose of MSG. It indicated that a higher dose of MSG will affect more necrotic cells, relevant to Halomoan et al study showing higher doses and longer duration of MSG increased pyramidal cell degeneration in hippocampus CA1 (Halomoan et al., 2013). Kruskal-Wallis indicated percentage significant difference ( $p = 0,000$ ) between all groups. Mann-Whitney test showed a significant difference ( $p = 0.004$ ) between GI and GII; GI and GIII; and GI and GIV. Based on Mann-Whitney test, a significant difference was shown between MSG administration group.

High doses of MSG affected numbers of necrosis in pyramidal cells in cortex cerebri. This was due to the increasing concentration of glutamate in the brain, as consequences of higher circulated glutamate in blood after MSG intake. Though glutamate needs to be converted to glutamine in order to enter the brain via blood-brain barrier (Anurogo and Ikrar, 2014). Excessive glutamate concentration induces cells death through autophagy by lysosome. Uncontrolled lysosome activity would lead to internal destruction and end in necrosis (Wang and Qin, 2010).

## 5. Conclusion

There were significant differences of pyramidal cells necrosis numbers between control and the treatment groups. MSG doses 6, 12, and 24 mg/grbb/day developed the pyramidal cells necrosis in the cerebral cortex. A higher dose of MSG administration led to higher number of necrotic pyramidal cells.

## References

- Anurogo, D. and Ikrar, T. (2014), "The Neuroscience of Glutamate". *Ethical Digest*, X, pp. 55–61.
- Baehr, M. & Frotscher, M. (2007), *Diagnosis Topik Neurologi Duus*. Jakarta: EGC.
- Bagley, J., Moghaddam, B. and Haven, W. (1997), "Temporal Dynamics of Glutamate Efflux in The Prefrontal Cortex and In the Hippocampus Following Repeated Stress: Effects of Pretreatment With Saline or Diazepam", *Neuroscience*, 77(1), pp. 65–73. doi: 10.1016/S0306-4522(96)00435-6.
- Geha, R. S. et al. (2000), "Review of alleged reaction to monosodium glutamate and outcome of a multicenter double-blind placebo-controlled study", *The Journal of nutrition*, 130(4S), pp. 1058S–1062S. Available at: <http://www.ncbi.nlm.nih.gov/pubmed/10736382>.
- Halomoan, S., Muhartomo, H. and Pudjonarko, D. (2013), "Pengaruh Pemberian Monosodium Glutamat peroral terhadap Degenerasi Neuron Piramidal CA1 Hipokampus pada Tikus Wistar". *Medica Hospitalia*, 1, pp. 175–181.
- Lupinsky, D., Moquin, L. and Gratton, A., (2010), "Interhemispheric Regulation of the Medial Prefrontal Cortical Glutamate Stress Response in Rats". *Journal of Neuroscience*, 30(22), pp. 7624–7633. doi: 10.1523/JNEUROSCI.1187-10.2010.
- Mora, F. and G. Segovia, A, and del A. (2007), "Aging, Plasticity and Environmental Enrichment: Structural Changes and Neurotransmitter Dynamics in Several Areas of The Brain". *Brain Res. Rev*, 55, pp. 78–88.
- Prawirohardjono, W. et al., (2000), "The administration to Indonesians of monosodium L-glutamate in Indonesian foods: an assessment of adverse reactions in a randomized double-blind, crossover, placebo-controlled study", *The Journal of Nutrition*, 130(4S Suppl), p. 1074s–6s. Available at: <http://jn.nutrition.org/content/130/4/1074.full.pdf>.

- Priyantiningrum, A. and Kuswati, & Handayani, E. S. (2015), "Pengaruh Ekstrak Etanol *Centella asiatica* terhadap Jumlah Sel Neuron di Korteks Prefrontalis Tikus yang Diberi Perlakuan Stres". *JKKI*, 6.
- Sherwood, L. (2010), "Human Physiology: From Cells to Systems". *Human Physiology*, 7th edition, p. 766. doi: 9781111577438.
- Snell, R. (2002), "Clinical Anatomy by systems". In *Annals of surgery*, p. 759–766; discussion 767.
- Wang, Y. and Qin, Z. H. (2010) 'Molecular and cellular mechanisms of excitotoxic neuronal death', *Apoptosis*, 15(11), pp. 1382–1402. doi: 10.1007/s10495-010-0481-0.
- Xiong, J. S., Branigan, D. and Li, M. (2009), "Deciphering the MSG controversy". *International Journal of Clinical and Experimental Medicine*, 2(4), pp. 329–336.

**Corresponding author**

Nur Fardian can be contacted at [nurfardian@unimal.ac.id](mailto:nurfardian@unimal.ac.id).